

Vascular Malformations as a Cause of Postpartum Hemorrhage

K. Hayes

INTRODUCTION

Uterine vascular malformations (UVM) leading to postpartum hemorrhage (PPH) are rare. The worldwide literature consists of case reports and small case series, and while the true incidence is unknown, it is likely to represent a very small proportion of causes of PPH. UVM can be congenital but are more commonly acquired when they tend to present with secondary PPH, although in rare instances they present with primary or even tertiary bleeding¹. As a general rule, primary PPH occurring temporally close to delivery most likely is a result of a pre-existing arteriovenous malformation (AVM), whereas secondary or tertiary PPH is more likely due to an acquired pseudoaneurysm.

Secondary PPH occurs in up to 0.5–1.5% of pregnancies² and the vast majority of women who present with secondary or tertiary PPH will have endometritis with or without retained products of conception (RPOC). Their management usually consists of broad spectrum antibiotics and, if necessary, an evacuation of RPOC. The vast majority of these women stop bleeding thereafter. Because some women receive multiple courses of antibiotics and evacuation procedures without evidence of infection or RPOC, clinicians finally start to consider vascular malformations rather than persevering with repeated ineffective treatments.

VASCULAR MALFORMATIONS

Vascular malformations may be congenital or acquired and consist of true AVMs, arteriovenous fistulae and pseudoaneurysms.

Congenital arteriovenous malformations

Congenital AVMs are abnormal arteriovenous connections that can occur anywhere in the body. These are rare as primary uterine lesions and no true estimate of their incidence is possible. The majority are usually found in the head and neck, and a 10 year review in a tertiary referral vascular center found only one uterine case out of 145 AVMs³. They result from abnormal development of primitive vessels that form connections between pelvic arteries and veins in the uterus⁴.

They are characterized by several feeding and draining vessels with an interconnecting nidus with turbulent flow⁵. When they occur in the uterus they have the potential to cause obstetric and/or gynecological bleeding. The majority of significant bleeds occur as a result of either iatrogenic intervention (uterine instrumentation) or placental implantation involving the AVM⁶.

AVMs are so rare that they are only likely to contribute truly to less than 1% of PPH. Moreover, the diagnosis is usually only made in a hysterectomy specimen or by interventional radiology on the basis of an arteriogram when bleeding is intractable and the patient remains stable enough for possible embolization.

Due to their rarity, the diagnosis of an AVM is usually retrospective if it is made at all. From the clinical point of view, the PPH is managed as any other PPH. Not surprisingly, however, many conservative measures fail to work, as it is likely that the abnormal vascular compartment of the AVM has been opened.

Acquired vascular malformations

Acquired vascular malformations invariably result from iatrogenic or traumatic injury to the uterine artery vascular bed⁷. This is particularly so when significant intractable secondary PPH occurs and where uterine artery pseudoaneurysm needs to be considered. A recent review of case reports and series of pseudoaneurysms¹ found 16 cases of which 10 had recently undergone cesarean section, three uterine evacuation procedures, and three had had normal spontaneous vaginal deliveries (of these, two had had previous gynecological surgery).

A pseudoaneurysm is characterized by a complete lack of vascular layers (intima, media and adventitia) surrounding the blood collection which communicates with the parent artery through the injury. The boundary of the 'aneurysm' is in fact the surrounding connective tissue. In terms of etiology, cesarean section at advanced dilatation with uterine angle extension is the commonest antecedent event, where direct trauma and suturing around the uterine artery bed cause abnormal vascular connections. Failure to

completely secure the bleeding vessels at the apex of an angular tear leads to leakage into the surrounding tissues. Recent curettage, particularly if difficult or if the placental tissue was very adherent, also can cause direct vascular trauma. When these abnormalities present after an uncomplicated vaginal delivery, it is proposed that the myometrial vascular bed is disrupted by the mechanics of delivery or, in fact, more likely the malformation pre-existed and only presented after delivery.

Due to the abnormal vascular connections, the normal controls over hemostasis fail, and increases in blood pressure due to activity lead to rupture of the fragile structure with blood draining from the lesion into the uterine cavity. This often happens spontaneously with no obvious provocation but may be exacerbated by repeated uterine evacuation. Bleeding may be intermittent, and it is proposed that the boundaries of the pseudoaneurysm act intermittently as a valve¹.

If the lesion is deeper into the myometrium and does not connect with the cavity, then a pelvic hematoma will ensue or rarely lead to an intraperitoneal hemorrhage. This is especially dangerous, as bleeding is covert and patients may delay seeking medical help.

CLINICAL PRESENTATION

When should a clinician suspect this rare phenomenon? The following characteristics are most indicative of a pseudoaneurysm as the underlying cause of a PPH:

- (1) There is usually secondary heavy vaginal bleeding.
- (2) There are repeated episodes of bleeding requiring medical attention with secondary or tertiary PPH.
- (3) Many women will even have received one or more blood transfusions.
- (4) Bleeding is usually painless.
- (5) There is usually a history of recent emergency cesarean section (typically at advanced dilatation) or uterine curettage.
- (6) There is a failure to respond to medical treatment or uterine evacuation.
- (7) There is no evidence of an alternative cause such as infection or RPOC on transvaginal sonography.

The recent review of 16 cases of pseudoaneurysm outlined above, reported in 15 centers, were diagnosed at a mean of 18 days postpartum with a range from 3 hours to 76 days postdelivery¹. In this clinical situation when faced with recurrent disproportionately heavy bleeding that has failed to respond to 'routine management' with no apparent underlying cause, the need for senior input and a search for a vascular malformation should be apparent.

DIAGNOSIS

Diagnosis is likely only if sufficient clinical suspicion exists, as the pseudoaneurysm may be small and easy to miss¹. Although angiography is considered the gold standard diagnostic test for vascular abnormalities, good quality transvaginal sonography with Doppler is generally the initial key to diagnosis. Transvaginal sonography will be diagnostic for most cases, and Abu Ghazza *et al.*¹ showed that transvaginal sonography alone was diagnostic in 12 of the aforementioned 16 cases of pseudoaneurysm. The use of transvaginal sonography not only makes the diagnosis, but also lateralizes the lesion so that management can be directed more selectively. The following characteristics establish the diagnosis of pseudoaneurysm on transvaginal sonography:

- A discrete mass usually in the right or left paracervical region (see Figures 1 and 2)
- Doppler flow within the mass showing a 'to and fro' mixed pattern in diastole and systole (see Figures 3 and 4)

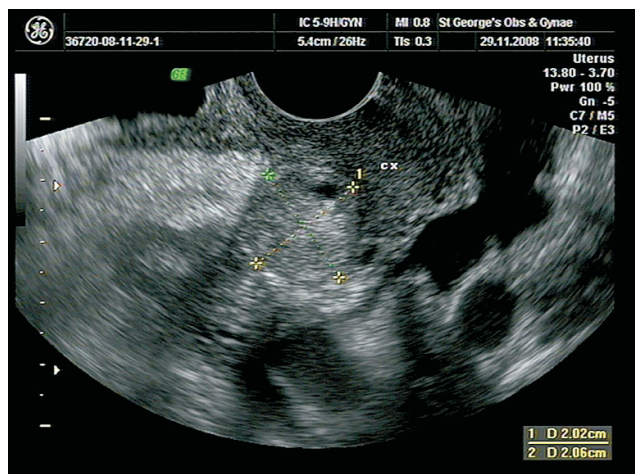

Figure 1 An inhomogeneous mass in the left paracervical region on transvaginal sonography in longitudinal section

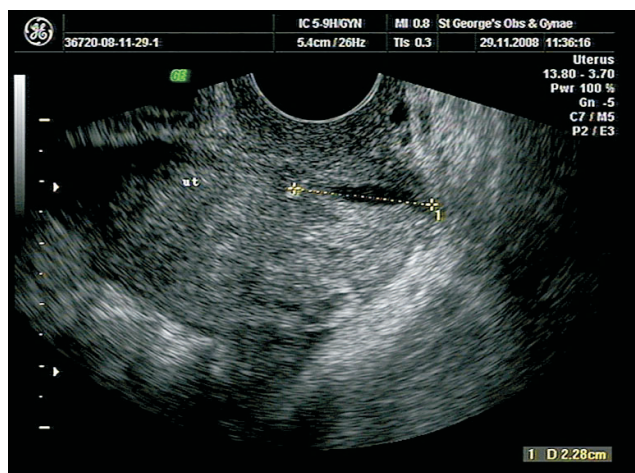


Figure 2 The same mass in transverse section demonstrating vascular caliber

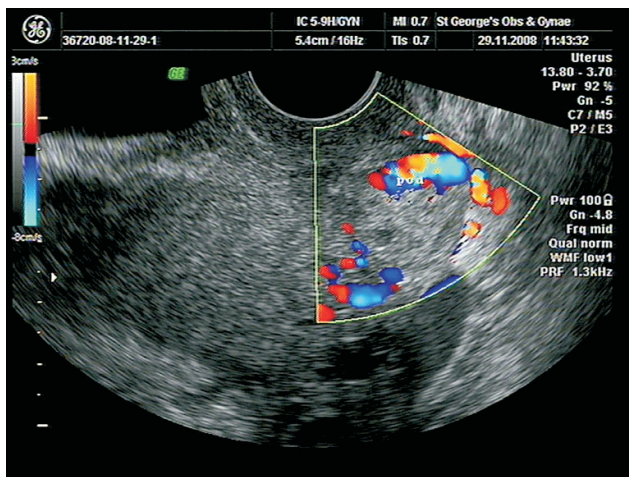


Figure 3 The same mass in Figure 2 with Doppler demonstrating mixed 'to' flow in systole

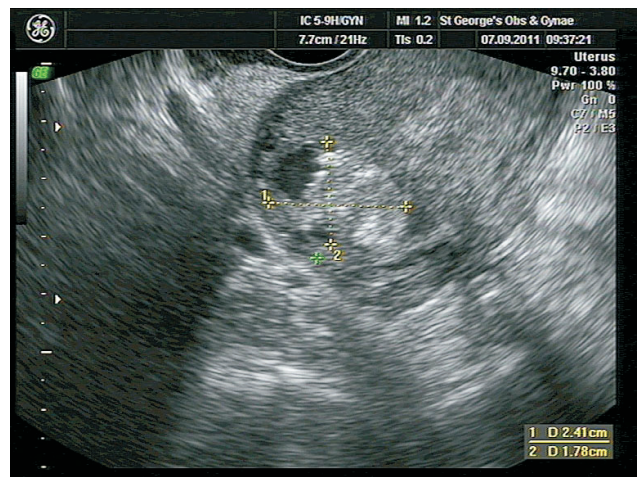


Figure 5 A mass is seen in the right upper myometrial region in transverse section

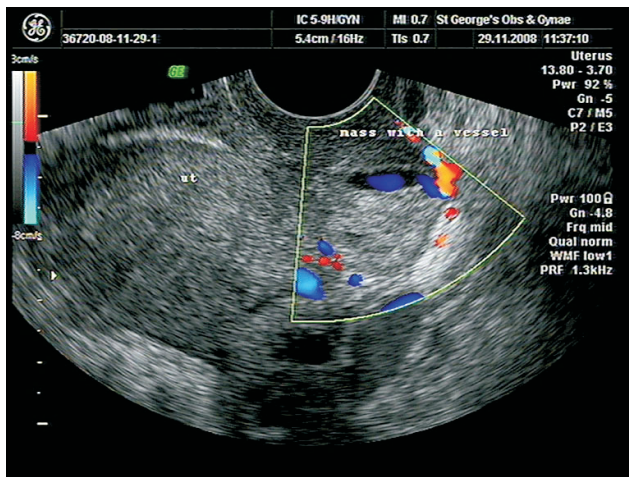


Figure 4 The same mass in Figure 2 with Doppler demonstrating 'fro' flow in diastole

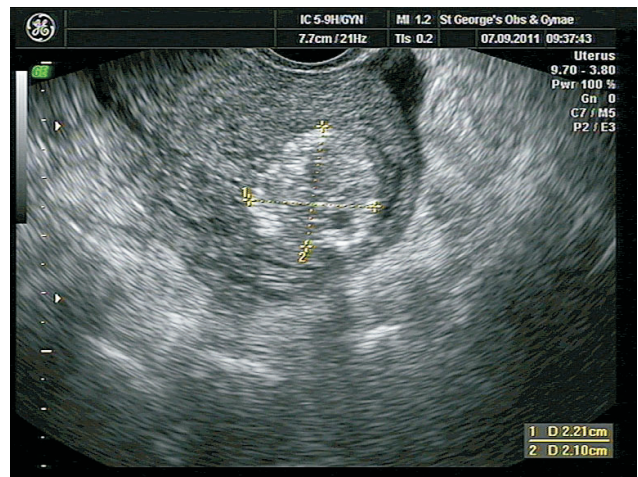


Figure 6 The same mass seen in longitudinal section

- Doppler flow within the mass showing turbulent mixed flow
- No evidence of products of conception in the uterine cavity.

In this clinical situation differential diagnosis of a mass includes an incidental fibroid, hematoma, or an abscess. The characteristic vascular appearance with the 'to and fro' sign first described by Abu-Yousef *et al.* in 1988⁸ is only seen in a pseudoaneurysm and differentiates a pseudoaneurysm from the other diagnoses. It is important to image the whole myometrium and paracervical regions, as the pseudoaneurysm may also be found in both of these sites^{9,10}. The other characteristic sonographic pattern is high flow with low resistance on Doppler examination^{11,12}. The same is true if congenital AVM is suspected, as by definition they invariably lie within the myometrium. Figures 5–8 are transvaginal sonography images of a congenital AVM that was diagnosed in the author's unit after primary major PPH that fortunately diminished spontaneously.

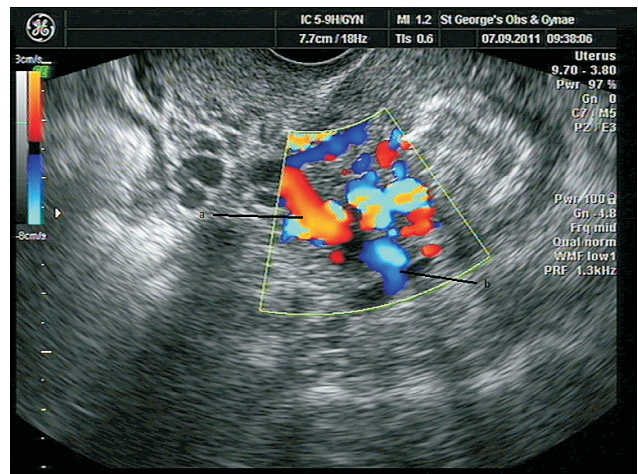


Figure 7 A congenital AVM demonstrating a feeding artery (arrow a) and draining vein (arrow b)

Computed tomography (CT) and magnetic resonance imaging (MRI) angiography are increasingly used in the diagnosis of pseudoaneurysm¹³, and MRI in particular seems to be at least as good as transvaginal

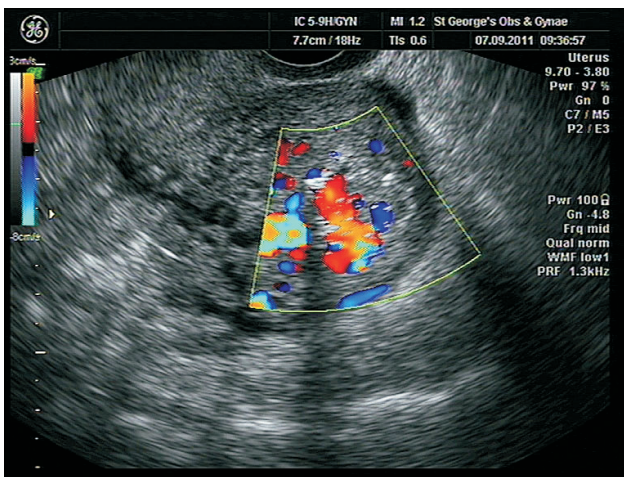


Figure 8 The same AVM as shown in Figure 7 showing a different pattern of flow during a single examination

sonography, though not necessarily any better in terms of sensitivity⁴. Due to the extra cost and sparse availability of these latter diagnostic modalities, MRI is only likely to be helpful where there is doubt over the diagnosis on transvaginal sonography and where invasive angiography may be avoided, where transvaginal sonography is negative but clinical suspicion is high or when the diagnosis has not been considered specifically and MRI picks it up as an 'incidental finding'.

Because of the high pick up rates associated with transvaginal sonography and other imaging techniques, angiography will generally be used as a confirmatory test for definitive management with the added advantage of mapping the vascular tree including any collateral supply to the malformation. Endovascular treatment can obviously be performed at the same time.

MANAGEMENT

By the time the diagnosis is considered, the patient will already have received antibiotics and will often have had at least one evacuation of retained products of conception (ERPC). Inevitably this fails to resolve the problem and bleeding either continues or resumes after an initial period of quiescence; bleeding is usually heavy and hemodynamic support including blood transfusion is common. In this situation the following need to be considered:

- Seek senior obstetric help
- Continue hemodynamic support if required
- Do not instrument the uterus further unless there is convincing evidence of RPOC on ultrasound
- If pseudoaneurysm is considered, then expert transvaginal ultrasound examining the paracervical regions, adnexae along the uterine artery, the myometrium in its entirety and the broad ligaments has a high pick up rate

- In theory, uterine balloon tamponade may be effective with a known pre-existing congenital AVM or pseudoaneurysm if pressure is applied to the discrete area that is bleeding. This will only be temporary to stabilize the patient before definitive treatment
- Once diagnosed, discuss the case with interventional radiology – an arteriogram will confirm the transvaginal sonography findings
- Selective uterine artery embolization is usually simple to perform at this time and its efficacy can be seen immediately with a postembolization angiogram
- In the presence of continued uterine bleeding despite selective embolization, then bilateral uterine artery embolization or internal iliac anterior division embolization may be possible, particularly if the arteriogram demonstrates any collateral supply from other pelvic vessels
- Postprocedural care should be routine as long as there is no significant bleeding from the uterus and/or femoral puncture sites
- De-briefing regarding future pregnancies is important – fertility should be essentially unchanged and there are no major obstetric issues regarding future antenatal care or delivery
- Ultimately hysterectomy is the treatment of last resort if uterine bleeding is intractable despite the above measures or hemodynamic instability makes interventional radiology inappropriate.

Embolization of the pelvic vascular system is not only a well established treatment for PPH in general (see Chapter 49), but also has been shown to be particularly useful in the context of a demonstrable discrete vascular malformation. The advantages of this procedure are that it is minimally invasive and can be performed under local anesthesia, it preserves the uterus and if the site of hemorrhage can be accurately identified, selective embolization can be performed with minimal disruption of the normal vascular supply to the uterus¹. The source of hemorrhage may be identified as either an abnormality of the parent artery such as a pseudoaneurysm or by contrast extravasation. If such a source is not readily identified, however, empirical embolization of the uterine arteries or anterior divisions of the internal iliac arteries bilaterally can still be performed. In addition angiography may identify alternative, unsuspected sources of hemorrhage which can similarly be embolized. The literature describes a high degree of success in managing vascular malformations with embolization, though it is impossible to quote a success rate, as intrinsic bias exists when failed cases leading to hysterectomy are likely to be either not reported or at best under-reported. Figures 9 and 10 demonstrate angiographically confirmed pseudoaneurysms in two different patients, and Figures 11 and 12 show the contrast extravasation into the uterine cavity in the latter patient followed by its cessation after selective embolization.

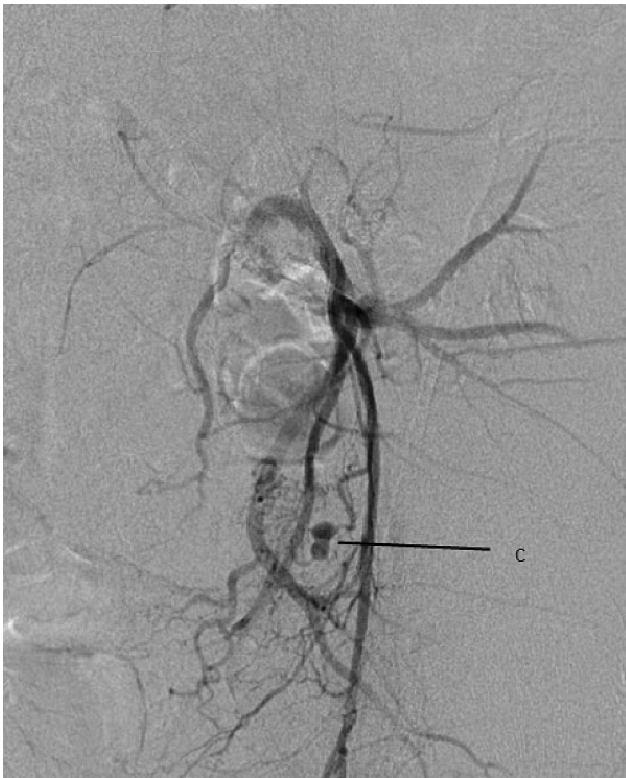

Figure 9 Angiographic 'proof' of a pseudoaneurysm of the right uterine supply diagnosed on transvaginal sonography – arrow c

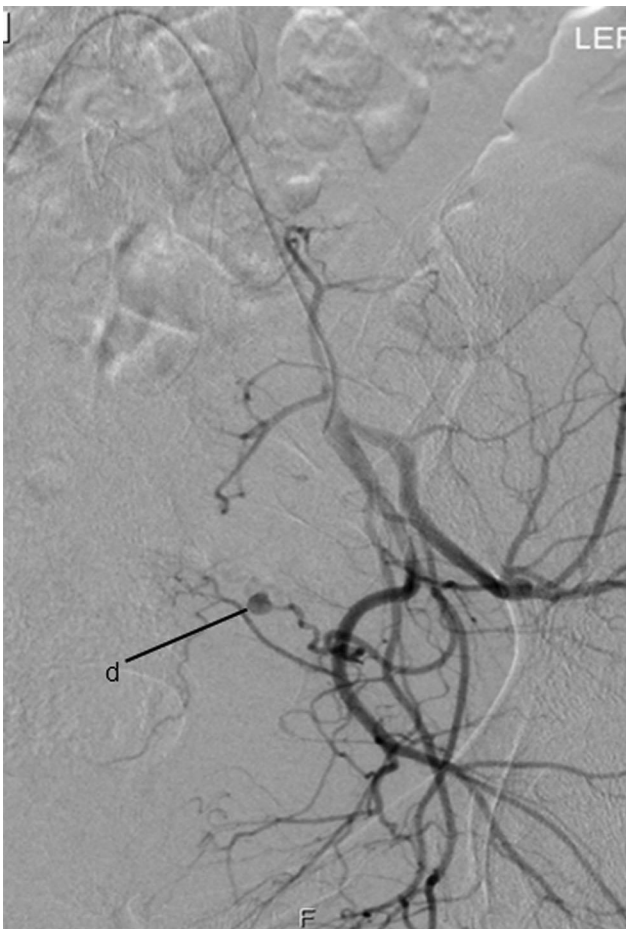


Figure 10 A second left pseudoaneurysm confirmed on angiography – arrow d

Embolization is performed with percutaneous catheterization of the femoral artery; the type of material used for embolization depends on the findings. Typically a temporary agent, gelatine sponge, is used for general PPH to reduce perfusion pressure, stop hemorrhage and allow eventual re-canalization. However, if a discrete vascular malformation such as pseudoaneurysm can be identified and a catheter introduced into it, particulate emboli, of which there are a variety, are usually used.

Clearly, the more proximal and non-selective the embolization, the greater the risk of compromise to the pelvic vascular supply subsequently. Pregnancies following embolization are reported including a series for known AVMs¹⁴, but the long-term reproductive sequelae are not yet defined, and the procedure itself carries potential documented morbidity including infection, neurological damage and bladder necrosis^{15,16}. These short- and long-term risks need to be weighed against the risk of PPH on an individual basis and discussed with the patient and her partner including honesty about the uncertainties of the current worldwide data.

A recent case report describes successful direct injection of embolization particles into a known lesion at laparotomy following failed endovascular embolization¹⁷, though this is a one-off case.

Ultimately hysterectomy is considered the only treatment if uterine bleeding is intractable despite the above measures or hemodynamic instability makes interventional radiology unsafe. It is clearly surgically important to get below the level of the origin of the pseudoaneurysm (usually the uterine artery) and tie off its supply or bleeding will inevitably continue.

In the rare cases where a known congenital AVM exists, PPH may be anticipated in a subsequent pregnancy or if there is the need for gynecological intervention. Unfortunately there is a paucity of evidence to guide whether expectant management or pre-pregnancy embolization is the most appropriate means to reduce the risk of future PPH. The likelihood of PPH is impossible to predict, but pragmatically if there is a normal obstetric history compared with a history of significant PPH this fact is likely to influence individual management. Elective embolization after a delivery can be considered to prevent future bleeding risk, but again the pros and cons should be discussed on an individual basis.

PREVENTION OF VASCULAR MALFORMATIONS

Clearly congenital malformations cannot be prevented, but pseudoaneurysm is nearly always due to iatrogenic causes. The vast majority of women with this problem have had obstetric or gynecological surgery as the underlying cause, many operations being emergency lower segment caesarean section at advanced dilatation but occasionally after curettage or open gynecological surgery.

Failure to secure angular tears of the uterus involving the uterine artery or one of its branches leads to

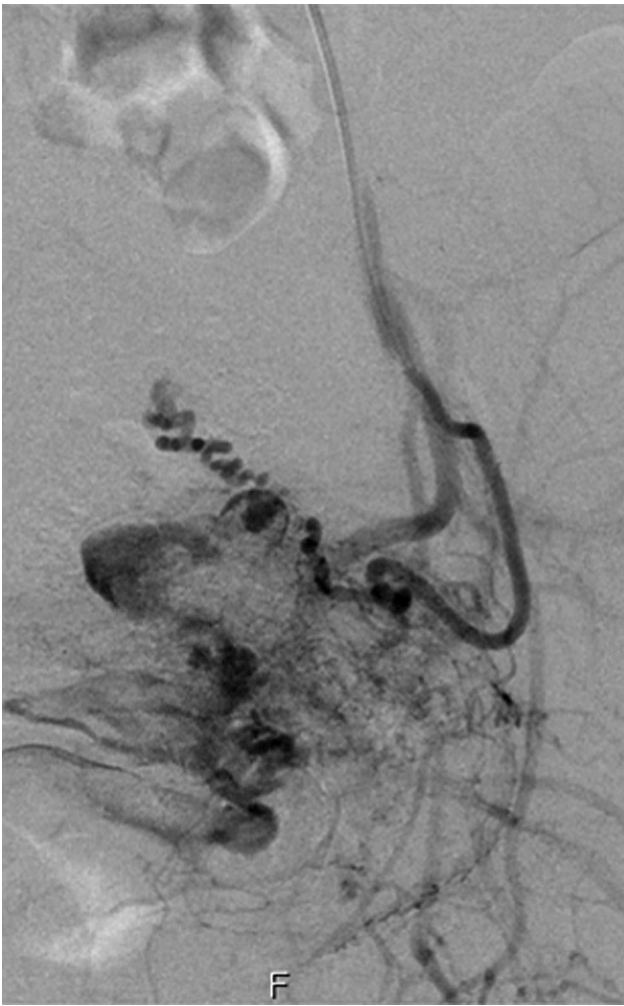


Figure 11 Contrast extravasation into the uterine cavity demonstrated in the pseudoaneurysm in Figure 10

pseudoaneurysm formation. All those who work in obstetric units understand that emergency lower segment cesarean section at full dilatation can lead to a difficult delivery, usually from occipital malposition and/or deflexion of the fetal head. Greater diligence when delivering the fetal head at advanced dilatation to try and prevent angular tears is very important; in the event that they occur, however, repairing them and ensuring the uterine vessels are completely secured should reduce the risk of pseudoaneurysm formation. Also, correcting any dextro-rotation of the uterus before incision will also reduce the risk of inadvertent uterine artery injury. Lesions seem to occur slightly more often on the left side, but are reported on both sides of the uterus.

CONCLUSION

Arteriovenous malformations are a rare phenomenon, and no clinician or center will deal with large numbers. They are undoubtedly more common than we realize, but many are likely to be clinically irrelevant, contributing only a very small proportion of the pathology causing PPH. When they do occur, however, they tend to cause a disproportionate amount of

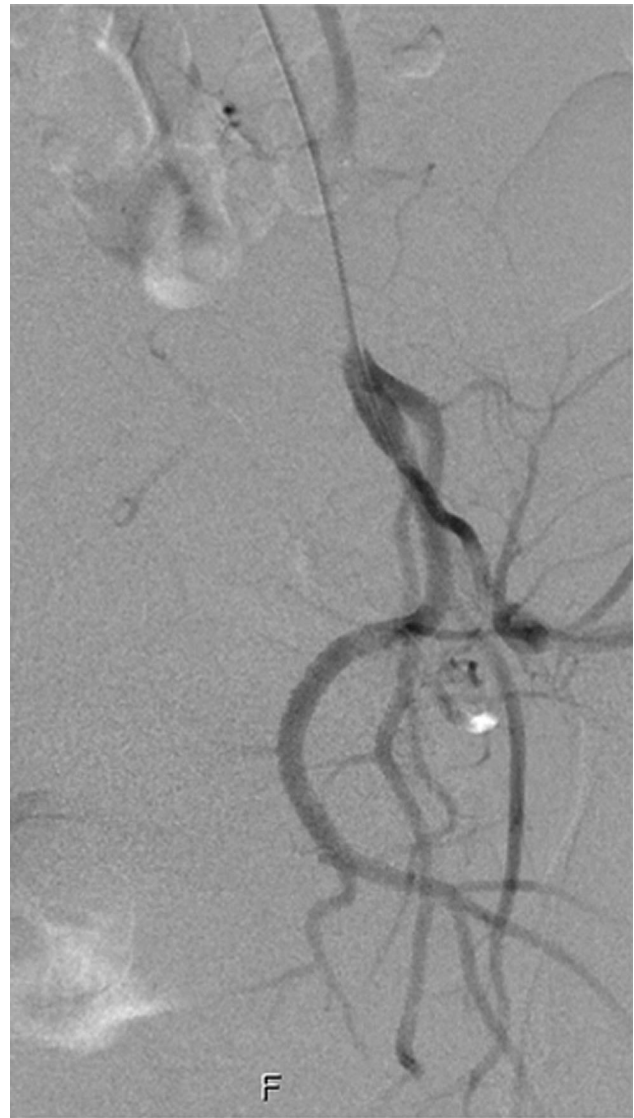

Figure 12 The same patient's angiogram demonstrating occlusion of the pseudoaneurysm after selective uterine artery embolization

bleeding. Little or nothing can be done about congenital AVMs, as they cannot be predicted. Regardless, they need serious consideration when acute primary PPH is intractable; these patients usually end up with embolization or hysterectomy as they respond poorly to conservative treatment.

Acquired pseudoaneurysms nearly always occur following lower segment cesarean section in advanced labor and more rarely after gynecological surgery. Although prevention is in theory possible, it is more important to have a high index of suspicion when there is sudden and major secondary PPH with little evidence of RPOC, a poor response to initial therapy and following a lower segment cesarean section in the late stages of labor.

Good quality transvaginal ultrasound with Doppler studies will diagnose most lesions, which can be confirmed on arteriography. Further uterine instrumentation should be avoided as this will exacerbate the problem; selective uterine artery embolization is a highly effective treatment with few side-effects. If

recognized in a timely fashion, the need for peripartum hysterectomy can usually be avoided with preservation of a woman's future fertility.

PRACTICE POINTS

- Arteriovenous malformations are a rare but important cause of PPH, usually secondary
- AVMs are usually associated with a history of emergency lower segment cesarean section in the late stages of labor
- AVMs are characterized by heavy bleeding with no other apparent cause that fails to respond to conservative and medical treatment
- High quality transvaginal ultrasound is an excellent diagnostic tool if clinical suspicion is sufficiently high
- Uterine artery embolization is the highly effective treatment of choice.

References

1. Abu-Ghazza O, Hayes K, Chandharan E, Belli AM. Vascular malformations in relation to obstetrics and gynaecology: diagnosis and treatment. *The Obstetrician Gynaecologist* 2010;12:87–93
2. Uchil D. Complications of the puerperium. In: Arulkumaran S, et al. eds. *The Management of Labour*, 2nd edn. Andhra Pradesh, India: Orient Longman, 2005
3. Kim JY, Kim DI, Do YS, et al. Surgical treatment for congenital arteriovenous malformation: 10 years' experience. *Eur J Vasc Endovasc Surg* 2006;32:101–6
4. Cura M, Martinez N, Cura A, Dalsaso TJ, Elmerhi F. Arteriovenous malformations of the uterus. *Acta Radiol* 2009;50:823–9
5. Tanaka R, Miyasaka Y, Fujii K, Kan S, Yagashita S. Vascular structure of arteriovenous malformations. *J Clin Neurosci* 2000;7:24–8
6. Grivell RM, Reid KM, Mellor A. *Uterine arteriovenous malformations: a review of the current literature.* *Obstet Gynecol Surv* 2005;60:761–7
7. Kwon JH, Kim GS. Obstetric iatrogenic arterial injuries of the uterus: diagnosis with US and treatment with transcatheter arterial embolization. *Radiographics* 2002;22:35–46
8. Abu-Yousef M, Wiese J, Shamma A. The “to and fro” sign: duplex Doppler evidence of femoral artery pseudoaneurysm. *AJR Am J Roentgenol* 1988;150:632
9. Eason D, Tank R. Avoidable morbidity in a patient with pseudoaneurysm of the uterine artery after Caesarean section. *J Clin Ultrasound* 2006;34:407–11
10. Ho S. A case of uterine pseudoaneurysm. *Singapore Med J* 2002;43:202–4
11. Kelly SM, Belli AM, Campbell S. Arteriovenous malformation of the uterus associated with secondary postpartum hemorrhage. *Ultrasound Obstet Gynecol* 2003;21:602–5
12. Müngen E, Yergök YZ, Ertekin AA, Ergür AR, Uçmakli E, Aytacılar S. Color Doppler sonographic features of uterine arteriovenous malformations: report of two cases. *Ultrasound Obstet Gynecol* 1997;10:215–9
13. Grivell RM, Reid KM, Mellor A. *Uterine arteriovenous malformations: a review of the current literature.* *Obstet Gynecol Surv* 2005;60:761–7
14. Delotte J, Chevallier P, Benoit B, Castillon JM, Bongain A. Pregnancy after embolization therapy for uterine arteriovenous malformation. *Fertil Steril* 2006;85:228
15. Hare WSC, Holland CJ. Paresis following internal iliac artery embolization. *Radiology* 1983;146:47–51
16. Sibour PR. Bladder necrosis secondary to pelvic artery embolization: case report and literature review. *J Urol* 1994; 151:422
17. Przybojewski SJ, Sadler DJ. Novel image-guided management of a uterine arteriovenous malformation. *Cardiovasc Intervent Radiol* 2011;34(Suppl 2):S161–6